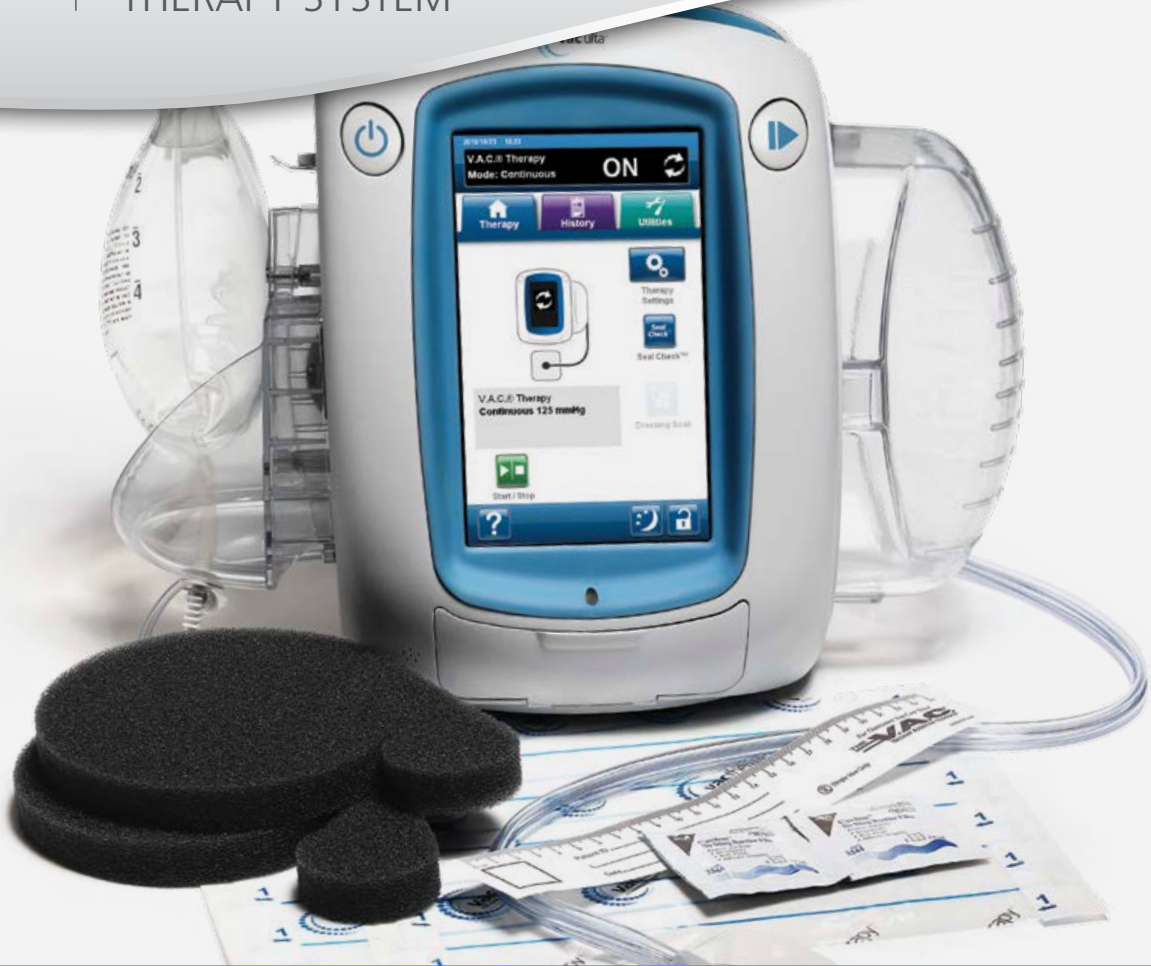



V.A.C.ULTA™ NEGATIVE PRESSURE WOUND THERAPY SYSTEM



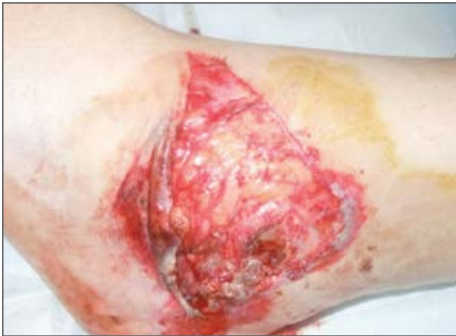V.A.C.Ulta™ Negative Pressure Wound Therapy System for V.A.C. VeraFlo™ Therapy Collection of Case Studies

The following case studies are the results of physicians' clinical experience. As with any case study, the results and outcomes should not be interpreted as a guarantee or warranty of similar results. Individual results may vary depending on the patient's circumstances and condition.

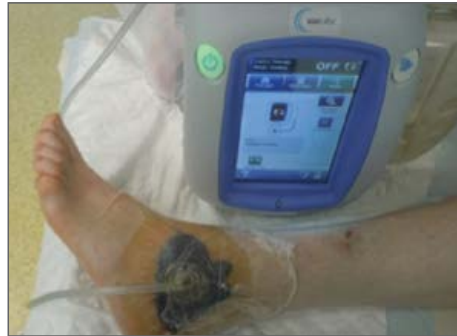Case Study 1:

Trauma of the Ankle

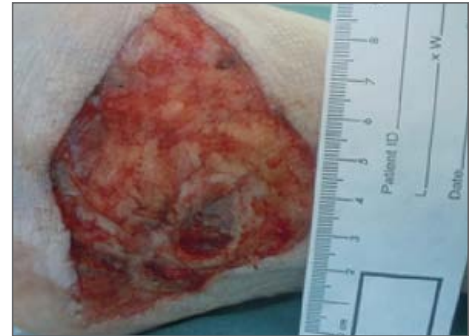Patient was a 69-year-old female, with a history of arterial hypertension, who presented with an open fracture of the left lateral malleolus. An initial large surgical debridement was performed, followed by V.A.C. VeraFlo™ Therapy for 9 days. V.A.C. VeraFlo™ Therapy was initiated using a V.A.C. VeraFlo™ Dressing. Saline (0.9% NaCl) was instilled until the foam was filled, followed by a soak time of 10 minutes. Instillation was repeated every 6 hours, followed by continuous negative pressure at -125 mmHg. Dressing changes occurred on Days 3 and 6, with final removal on Day 9. A thin hydrocolloid dressing was applied around the wound edges for extra skin protection. After 9 days of therapy, there was rapid development of homogeneous granulation tissue and a clean appearance of the wound. A split-thickness skin graft (STSG) was applied on Day 10, and by Day 18, wound was completely closed.



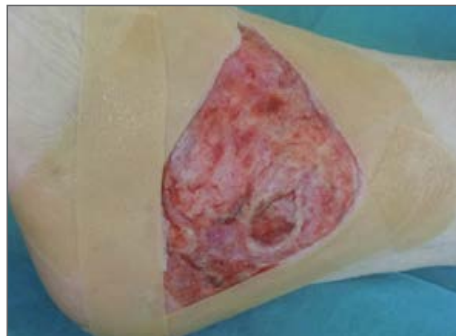A. Day 0: Presentation of an open fracture of the lateral malleolus of the left ankle



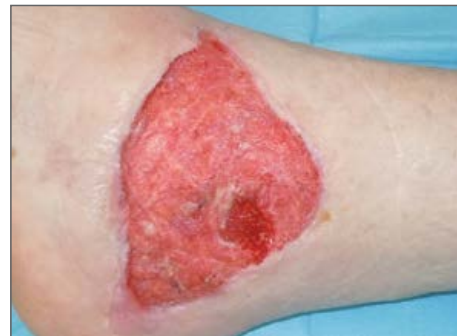B. Day 0: Application of V.A.C. VeraFlo™ Therapy



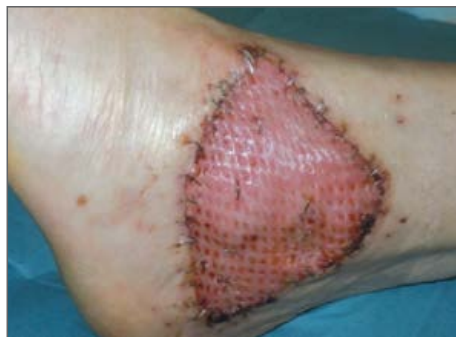C. Day 3: Wound after first dressing change



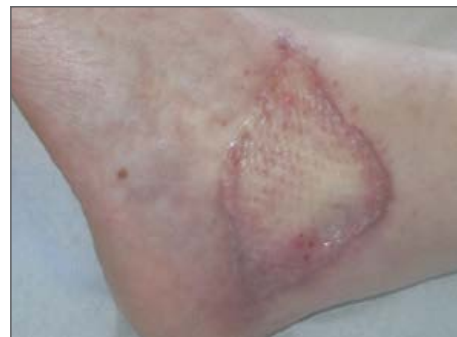D. Day 3: A thin hydrocolloid dressing applied around the wound edges for extra skin protection



E. Day 9: Rapid development of homogeneous granulation tissue with a clean appearance of the wound



F. Day 10: Application of STSG

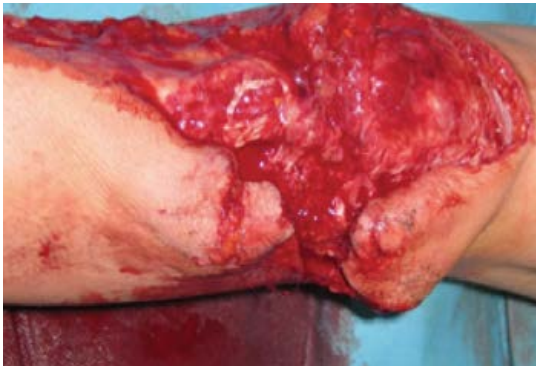

G. Day 18: Complete wound closure

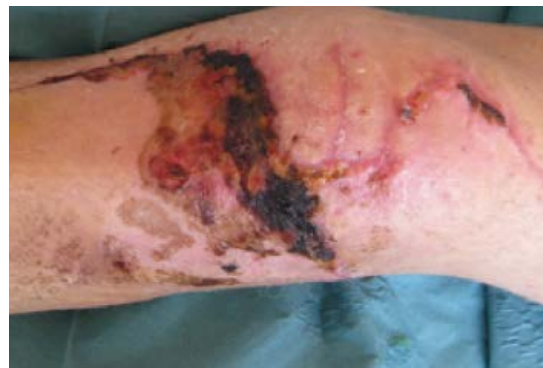Case Study 2:

Trauma of the Knee

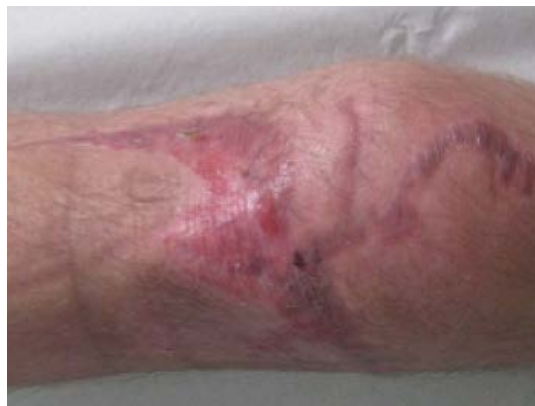Patient was a 22-year-old male, with no history of concomitant diseases, who presented with an open fracture of the left knee (comminuted fracture of the tibial plateau) with a skin defect on the anterior knee caused by a motorcycle accident. Extensive debridement was performed, followed by reconstruction of the bone with screws. Standard treatment, including pulsatile lavage and intravenous antibiotics, was initiated, but on Day 3, patient developed a skin infection with necrotizing bacteria based on both microbiologic data (ie, wound swabs and tissue samples) and clinical (eg, fever, redness, swelling, and pus) confirmation. On Day 6, debridement and articular lavage were performed, and V.A.C. VeraFlo™ Therapy was initiated using V.A.C. VeraFlo™ Dressings for 12 days. Saline (0.9% NaCl) was instilled until the foam was filled, followed by a soak time of 10 minutes. Instillation was repeated every 6 hours, followed by continuous negative pressure at -125 mmHg. Dressing changes occurred every 3 days with final dressing removal on Day 12 of therapy. Complete wound closure occurred 12 days after therapy was discontinued.



A. Initial presentation of open fracture of the left knee (comminuted fracture of the tibial plateau) with a skin defect on the anterior knee



B. Development of skin infection with necrotizing bacteria

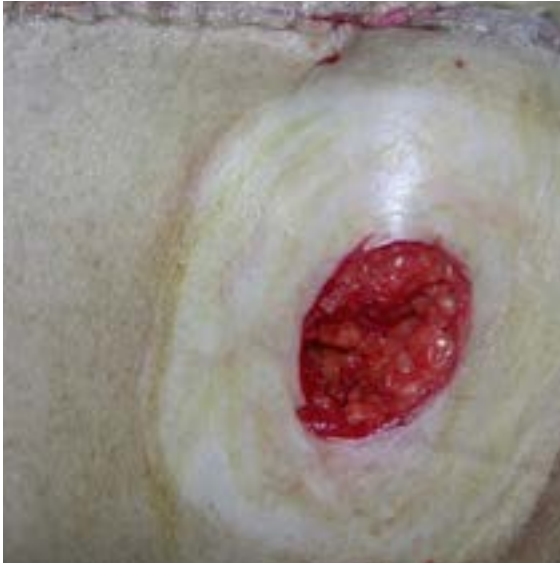

C. Complete wound closure occurred 12 days after therapy was discontinued

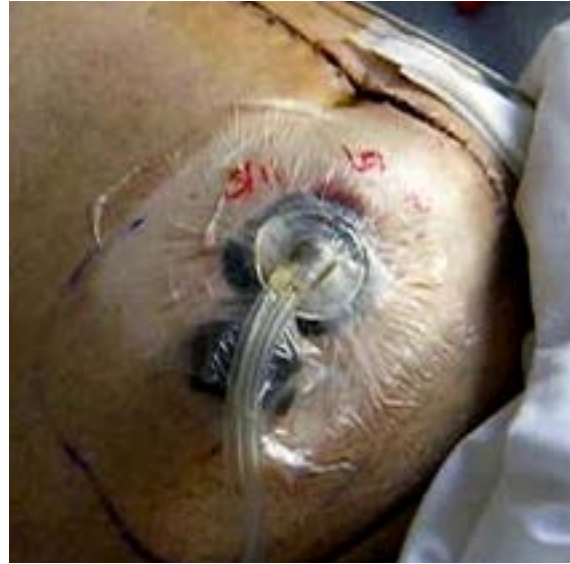Case Study 3:

Contaminated Ileostomy Site

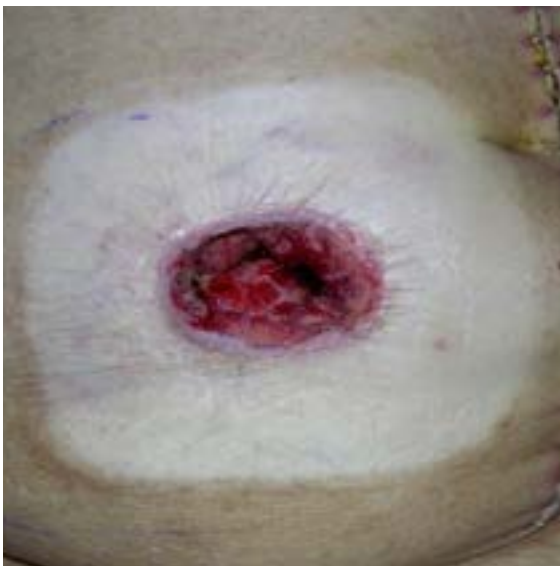An 83-year-old male presented with an open postoperative contaminated wound at a previous ileostomy site. V.A.C. VeraFlo™ Therapy was initiated using V.A.C. VeraFlo™ Dressing. Microcyn® (Oculus Innovative Sciences, Petaluma, CA) was instilled until the foam was filled followed by a soak time of 10 minutes. Instillation was repeated every 4 hours followed with continuous negative pressure at -125 mmHg for 12 days. Therapy was discontinued when patient transitioned out of the acute care setting and the wound could be treated with local wound care alone. No complications occurred during therapy.



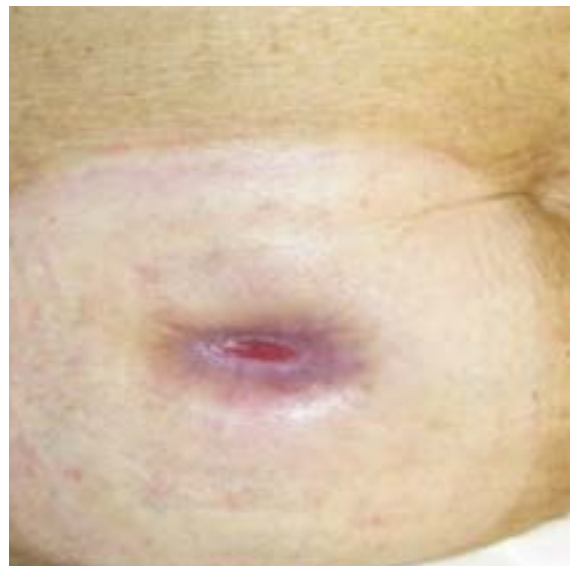
A. Immediate postoperative, right lower quadrant wound



B. Application of V.A.C. VeraFlo™ Therapy with instillation of Microcyn®



C. Day 10 of V.A.C. VeraFlo™ Therapy at 4th dressing change

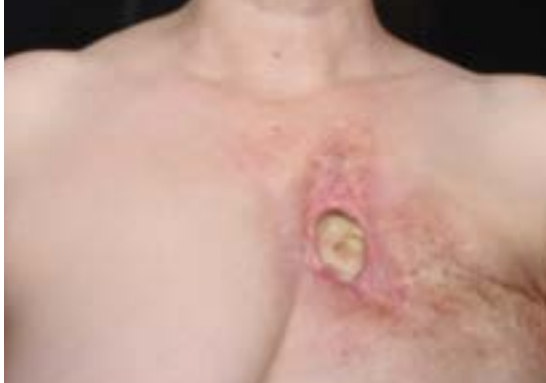

D. Follow up on postoperative Day 34

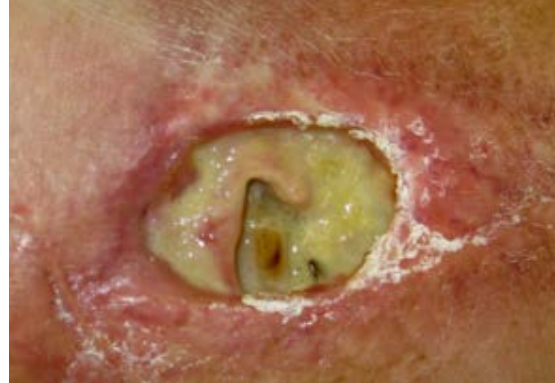Case Study 4:

Infected Chest Wound

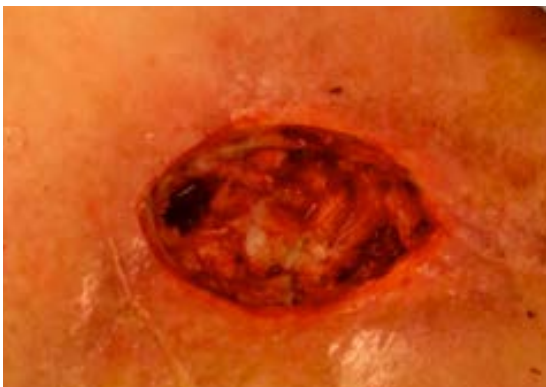
A 43-year-old female presented with an infected chest wound after radiation. Prior to debridement, the wound was visually assessed for infection. Punch-wound biopsy cultures were positive for bacterial bioburden. Patient received systemic antibiotics and wound was debrided. V.A.C. VeraFlo™ Therapy was initiated using V.A.C. VeraFlo™ Dressing. Prontosan® (B.Braun Medical Inc., Bethlehem, PA) was instilled until the foam was filled followed by a soak time of 3 minutes. Instillation was repeated every hour followed by continuous negative pressure at -125 mmHg for 3 days. No complications occurred during therapy, and granulation tissue was present with negative cultures at the time of coverage with a latissimus flap.



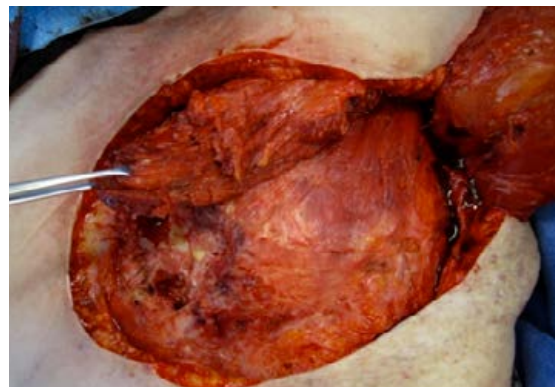
A. Radiated chest wound



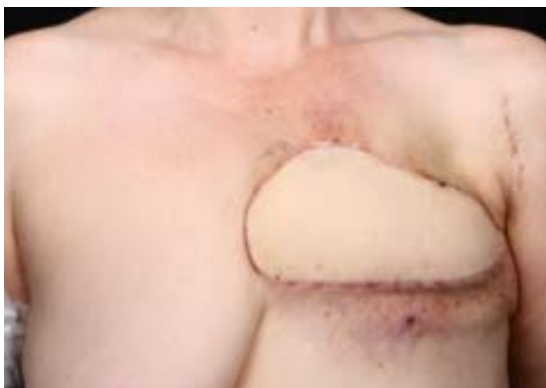B. Initial presentation of chest wound



C. Wound after debridement of rib and cartilage and 4 days of V.A.C. VeraFlo™ Therapy



D. Excision of radiated skin

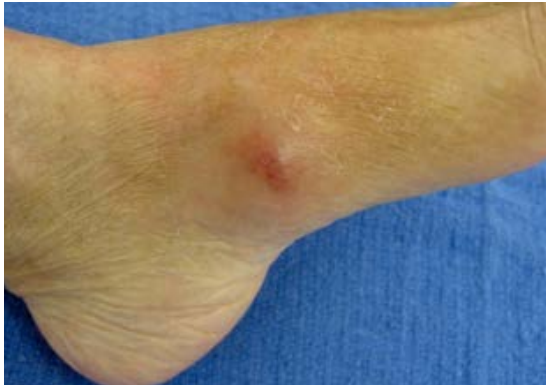

E. 6 weeks following chest wall reconstruction with latissimus flap

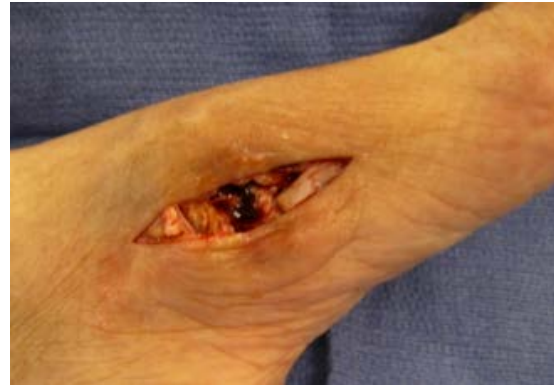Case Study 5:

Infected Foot Abscess

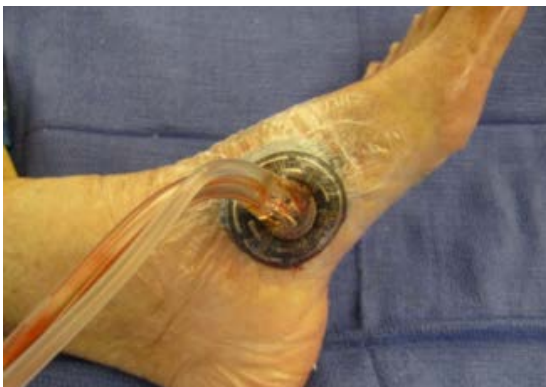An 86-year-old female diabetic with peripheral vascular disease presented with a left foot abscess. Prior to debridement, the wound was visually assessed for infection. Punch-wound biopsy cultures were positive for bacterial burden. Patient received systemic antibiotics and wound was debrided. V.A.C. VeraFlo™ Therapy was initiated using V.A.C. VeraFlo™ Dressing. Saline was instilled until the foam was filled, followed by a soak time of 3 minutes. Instillation was repeated every 2 hours, followed by continuous negative pressure at -125 mmHg for 3 days. No complications occurred during therapy, and granulation tissue was present with negative cultures at the time of primary closure.



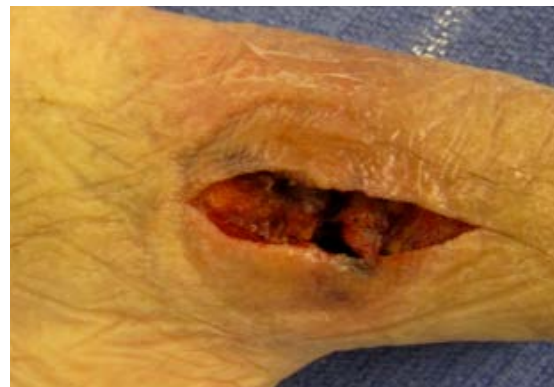A. Left foot abscess at presentation



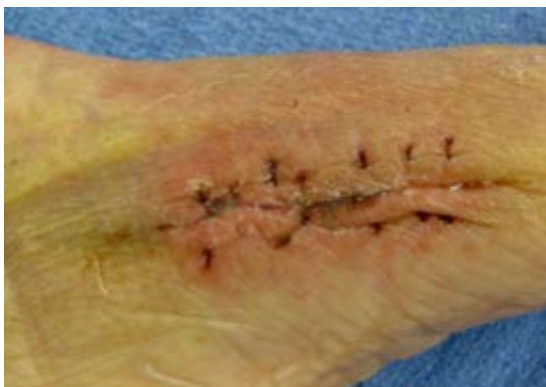B. Abscess was drained and the wound debrided



C. Application of V.A.C. VeraFlo™ Therapy



D. After 3 days of V.A.C. VeraFlo™ Therapy, wound was ready for primary closure

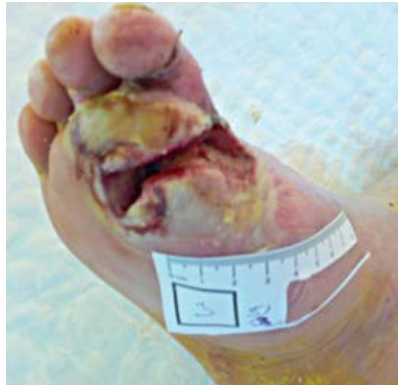

E. 2 weeks following primary closure

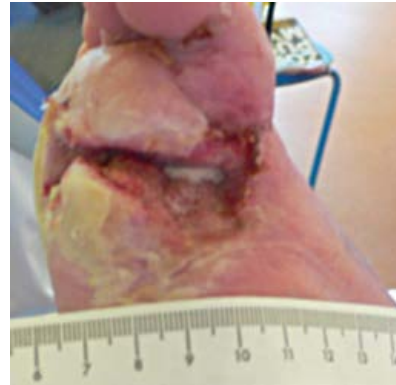
Case Study 6:

Infected Foot Wound

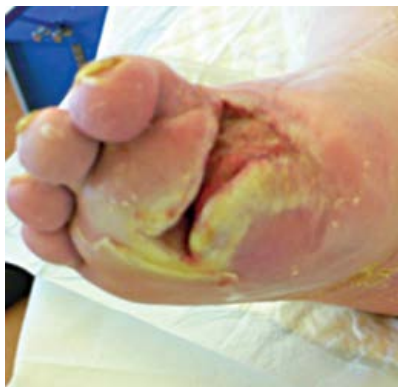A 74-year-old male with hypertension presented with an infected (limited growth of *Morganella morganii* and *Staphylococcus aureus* along with moderate growth of *Bacteroides fragilis*) neuropathic wound located on his right foot. After adequate debridement, V.A.C. VeraFlo™ Therapy was initiated using V.A.C. VeraFlo™ Dressing. Lactated Ringer's Solution (10mL) was instilled, followed by a soak time of 15 minutes. Instillation was repeated every 3.5 hours, followed by continuous negative pressure at -125 mmHg for 9 days. No complications occurred during therapy, and granulation tissue was present with no signs of infection based on clinical and culture results. The wound was then treated with V.A.C.® Therapy.



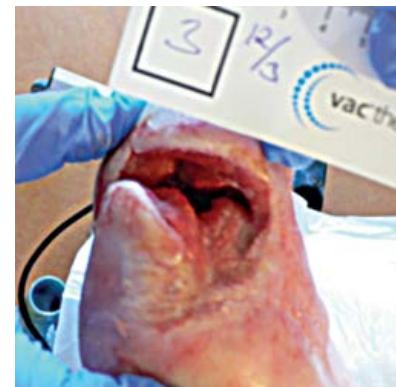A. Wound at initial presentation



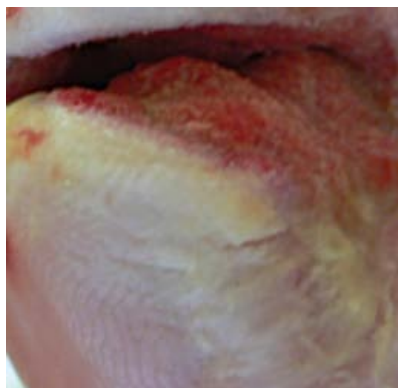
B. First dressing change



C. Second dressing change



D. Third dressing change

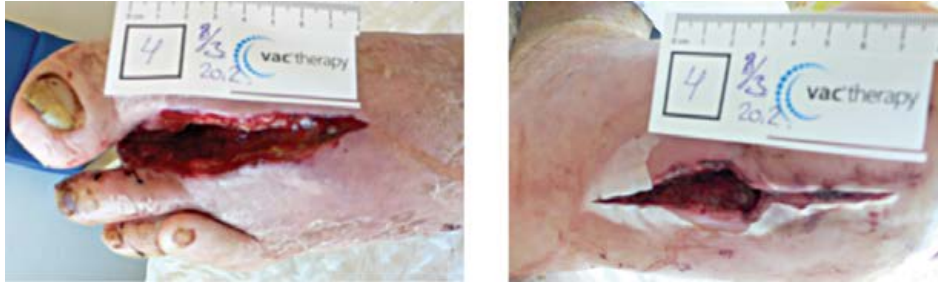


E. Wound after 9 days of V.A.C. VeraFlo™ Therapy

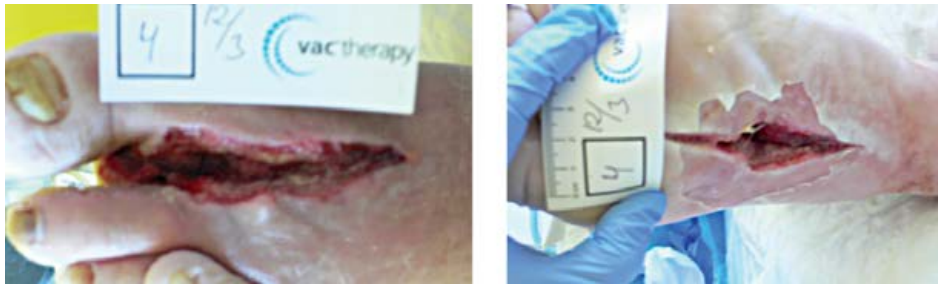Case Study 7:

Infected Diabetic Foot Wound

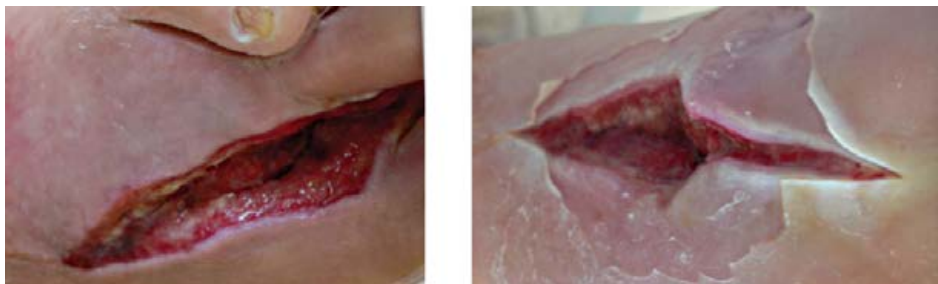
A 56-year-old male diabetic presented with an infected (moderate growth of *Streptococci*) diabetic foot ulcer. After adequate debridement, V.A.C. VeraFlo™ Therapy was initiated using V.A.C. VeraFlo™ Dressing. Lactated Ringer's Solution (22mL) was instilled, followed by a soak time of 15 minutes. Instillation was repeated every 3.5 hours, followed by continuous negative pressure at -125 mmHg for 6 days. No complications occurred during therapy, and granulation tissue was present with no signs of infection based on clinical and culture results. The wounds were then treated with V.A.C.® Therapy.



A. Wounds on top of foot (left) and bottom of foot (right) at initial presentation



B. Second dressing change on top of foot (left) and bottom of foot (right)

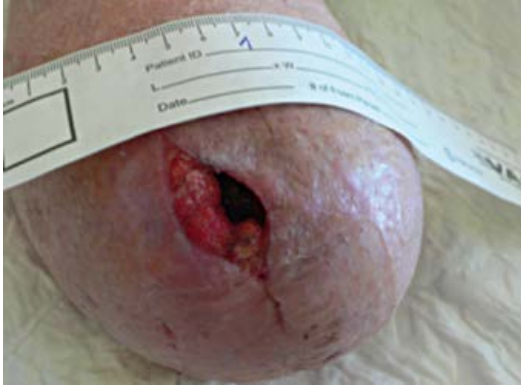

C. Wounds on top of foot (left) and bottom of foot (right) after 6 days of V.A.C. VeraFlo™ Therapy

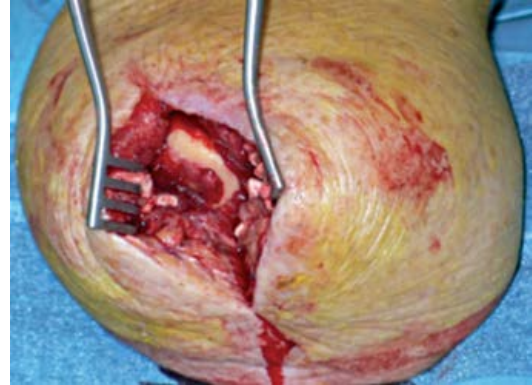Case Study 8:

Infected Trauma Wound

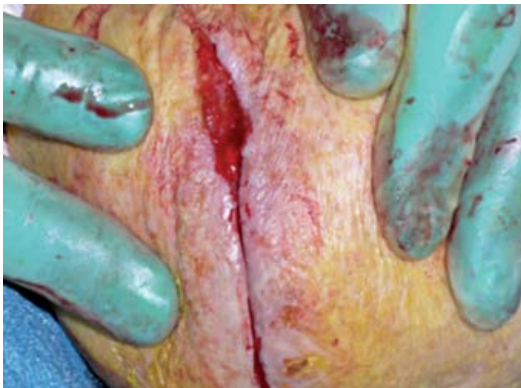A 67-year-old male presented with an infected (moderate growth of *Enterococcus faecalis*) trauma wound. After adequate debridement, V.A.C. VeraFlo™ Therapy was initiated using V.A.C. VeraFlo™ Dressing. Normal saline was initially used; 10mL was instilled, followed by a soak time of 15 minutes. Instillation was repeated every 3.5 hours, followed by continuous negative pressure at -125 mmHg for 7 days. The instillant was changed to Lactated Ringer's Solution at first dressing change. No complications occurred during therapy, and the wound was clean and closed by primary intention.



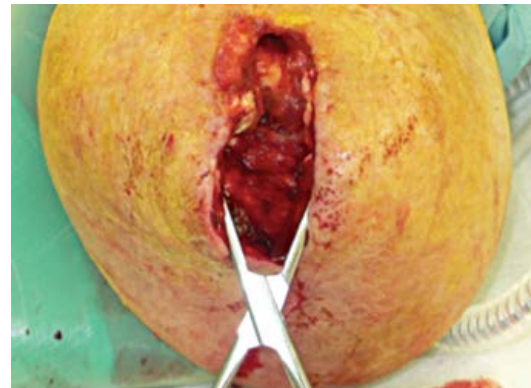A. Wound at initial presentation



B. First dressing change followed by surgical debridement



C. Second dressing change followed by surgical debridement



D. Wound after 7 days of V.A.C. VeraFlo™ Therapy

V.A.C.Ultra™ and V.A.C. VeraFlo™ Therapy Components

Solution
Container
Hanger Arm

Canister

Instillation Cassette
(V.A.C. VeraLink™ Cassette)



V.A.C. VeraFlo™
Dressing Kit



V.A.C. VeraFlo Cleanse™
Dressing Kit

V.A.C.ULTA™ SYSTEM ORDERING INFORMATION

Part Number	Description
ULTDEV01/US	V.A.C.Ultra™ Therapy Unit, United States
ULTVFL05SM	V.A.C. VeraFlo™ Dressing, 5-pack, Small
ULTVFL05MD	V.A.C. VeraFlo™ Dressing, 5-pack, Medium
ULTVCL05MD	V.A.C. VeraFlo Cleanse™ Dressing, 5-pack, Medium
ULTLNK0500	V.A.C. VeraLink™ Cassette, 5-pack
400230	Prontosan® Wound Irrigation Solution with Adapter, case of 10
ULTDUO0500	V.A.C. VeraT.R.A.C. Duo™ Tube Set, 5-pack
M8275063/5	500 mL InfoV.A.C.® Canister with Gel
M8275093/5	1,000 mL InfoV.A.C.® Large Canister with Gel

*V.A.C.Ultra™ Therapy Unit is compatible with all the InfoV.A.C.® Canisters



For more information about the V.A.C.Ultra™ Therapy System, contact us at **1-800-275-4524** or visit **www.vaculta.com**



NOTE: Specific indications, contraindications, warnings, precautions and safety information exist for KCI products and therapies. Please consult a physician and product instructions for use prior to application. Rx Only.

©2012 KCI Licensing, Inc. All rights reserved. Microcyn is a trademark of Oculus Innovative Sciences, Inc. Prontosan is a trademark of B.Braun Medical, Inc. All other trademarks designated herein are proprietary to KCI Licensing, Inc., its affiliates and/or licensors.
DSL#14-0545.US • Lit# 29-D-304 • (REV. 9/14)

