

SNAP™ THERAPY SYSTEM MONOGRAPH

Table of Contents

Introduction 3

SNAP™ System Components – Literature Review 4

Clinical Evidence Supporting SNAP™ System 7

Technology for SNAP™ System11

Indications for Use11

SNAP™ System Componentes 12

Science Supporting SNAP™ System 14

SNAP™ THERAPY SYSTEM - Literature Review. 14

Case Studies 15

Health Economics 22

References. 23

Preface

The SNAP™ THERAPY SYSTEM is a mechanically powered, disposable negative pressure wound therapy (dNPWT) system that uses constant force springs, rather than electrical power, to generate negative pressure.

This monograph will:

- Introduce SNAP™ System
- Review clinical literature reporting use of SNAP™ System
- Describe the components and technology of the SNAP™ System
- Summarize scientific evidence describing SNAP™ System mechanisms of action
- Present case studies demonstrating SNAP™ System application and outcomes
- Review a SNAP™ System health economics study

Introduction

An aging population and increasing prevalence of diabetes¹ have resulted in a growing number of patients with non-healing (chronic) wounds and ulcers^{2,3} being treated in the outpatient care setting.⁴ Venous leg ulcers⁵ and diabetic foot ulcers⁶ for example, are prone to recurrence – especially in older patients with age-impaired healing and multiple comorbidities (e.g., peripheral venous disease, diabetes, peripheral neuropathy).⁷ These wounds are a burden to patients, challenging to physicians, and costly to the healthcare system.^{3,8,9}

As research expands understanding of the wound healing process, increasingly sophisticated dressings and therapies have been developed to address barriers encountered during the sequential stages of healing.^{10,11,12} Negative Pressure Wound Therapy (NPWT) is an adjunctive therapy that applies sub-atmospheric pressure through a foam or gauze dressing to create an environment that promotes wound healing by drawing wound edges together, removing exudate and infectious material, reducing oedema.^{13,14} Since the initial US clearance for commercialization of NPWT (V.A.C.® Therapy, KCI, an ACELITY Company, San Antonio, TX, USA) in 1995, NPWT has been used effectively in a wide variety of acute and chronic wounds.¹⁵

While NPWT was initially available only for inpatient wound treatment, over time, a variety of portable NPWT systems have been developed for use across the continuum of care. The majority of these are electrically powered; however, recently a mechanically powered NPWT system, SNAP™ THERAPY SYSTEM, has been approved for management of wounds that would benefit from the use of NPWT to promote healing through the removal of small amounts of exudate, infectious material, and tissue debris. The single-use SNAP™ System is lightweight (<85g) (**Figure 1A**) to enhance patient mobility (**Figure 1B**), quiet (no electrical components), and designed for low-exudating wounds (≤180ml/week) that are less than 13cm x 13cm in area.¹⁶ This therapy is indicated for patients with chronic, acute, traumatic, sub-acute and dehiscent wounds, partial-thickness burns, ulcers (such as diabetic, pressure or venous insufficiency), flaps and grafts, and surgically closed incisions.

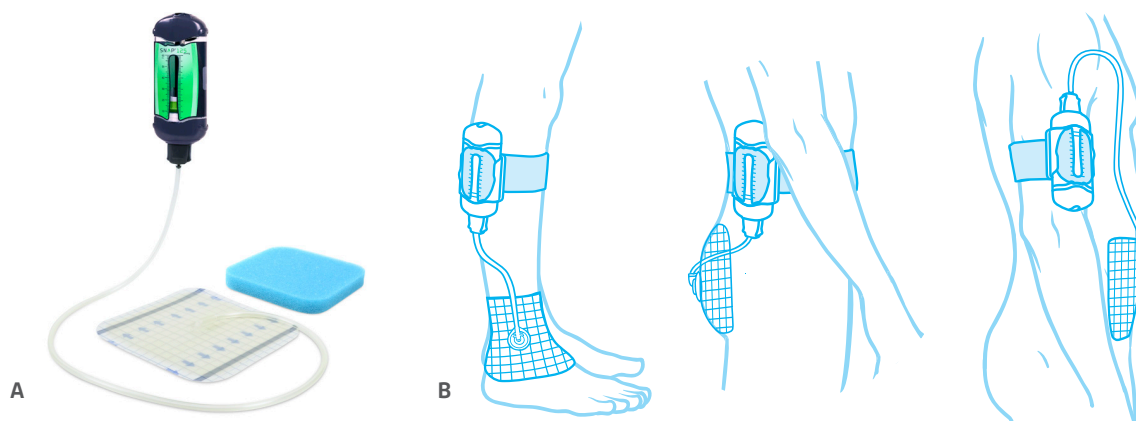


Figure 1. SNAP™ System: A) Lightweight cartridge, advanced hydrocolloid dressing and blue foam interface; B) Illustrations of SNAP™ System applied to a selection of wound types

Literature Review

A number of SNAP™ System studies have reported clinical outcomes for over 150 patients with a variety of wounds, including venous leg ulcers and diabetic foot ulcers. These studies, which include 2 randomized controlled trials (RCTs) as well as a number of case series and case studies, are discussed below and summarized in Table 1.

Percentage of wound size reduction at certain time points can also provide important information as to whether a treatment is likely to heal a wound.^{17,18} Studies have shown that diabetic foot ulcers achieving $\geq 50\%$ wound size reduction in 4 weeks (30 days)¹⁹ and $\geq 90\%$ wound size reduction in 8 weeks²⁰ were more likely to achieve healing in 12 weeks. Some SNAP™ System studies report complete wound closure data, while others focus on percent wound size reduction at specific time points.

The initial noninferiority RCT by Armstrong et al²¹ (2012) compared mechanically-powered SNAP™ System to electrically-powered V.A.C.® Therapy for 16 weeks in order to evaluate comparative efficacy between the groups for the primary endpoint of wound size reduction. A total of 132 patients with noninfected, nonischemic, nonplantar lower extremity diabetic and venous wounds were enrolled. Of these, 115/132 patients had follow-up data available for analysis, and 83/132 finished the study with either healing or 16 weeks of therapy: SNAP™ System, 41 patients; V.A.C.® Therapy, 42 patients. On average, baseline wound size was significantly larger for V.A.C.® Therapy wounds (SNAP™ System: 5.37 ± 6.14 vs V.A.C.® Therapy: 9.95 ± 11.38 ; $p < 0.05$). In terms of wound size reduction, SNAP™ System patients demonstrated noninferiority to V.A.C.® Therapy patients at 4, 8, 12 and 16 weeks ($p = 0.0030, 0.0130, 0.0051$, and 0.0044 , respectively). There were also no significant differences between the groups for complete wound closure at all time points and for device-related adverse events and complications (e.g., infection). Exit survey results showed that SNAP™ System patients reported less interruption of activities in daily living, less impact in overall activity, less interruption in sleep, less noise level, less impact on social situations, and wearability compared with V.A.C.® Therapy-treated patients. In this RCT, similar wound healing outcomes were demonstrated for SNAP™ System and V.A.C.® Therapy in the study population.²¹

In the second RCT (2015), Marston et al²² compared 40 patients with venous leg ulcers who completed the study with either healing or 16 weeks of therapy and were treated with either SNAP™ System ($n=19$) or V.A.C.® Therapy ($n=21$). The primary endpoint was wound size reduction. Although patients were randomized, there were differences in the mean initial wound size (mean \pm standard deviation) for SNAP™ System wounds ($4.85 \pm 4.49\text{cm}^2$) versus V.A.C.® Therapy wounds ($11.60 \pm 12.12\text{cm}^2$). There was no significant difference in the proportion of patients that completely healed over time (with [$p=0.4656$] or without [$p=0.3547$] adjustment for baseline wound size). In the SNAP™ System group, 52.6% (10/19) patients achieved the surrogate endpoint of 50% wound closure at 30 days, compared to 23.8% (5/21) V.A.C.® Therapy patients (odds ratio [OR] 3.56, 95% confidence interval [CI] of [0.923, 13.699]). Also, more SNAP™ System patients achieved complete closure at 90 days compared to V.A.C.® Therapy patients: 57.9% (11/19) patients vs 38.15% (8/21) patients, respectively (OR, 2.23, 95% CI [0.63, 7.93]).²²

The prospective comparative study by Lerman et al²³ (2010) compared wound care center (WCC) patients whose lower extremity venous or diabetic wounds were treated prospectively with SNAP™ System to matched historical control patients treated at the same center with skin substitutes or skin grafts. Wound healing outcomes for the prospective SNAP™ System patients were followed for up to 4 months. Of the 36 patients enrolled in the SNAP™ System group, 21 completed the study. The center's wound treatment database was then searched to identify matches by wound size and type, and additional patient characteristics (e.g., age, presence of diabetes or peripheral vascular disease). Each SNAP™ System patient was matched with 2 control patients resulting in a total of 42 historical controls that were included in the study. In the SNAP™ System group, 21/21 (100%) patients showed improvement in wound size, while 18/21 (86%) had a statistically significant ($p < 0.05$) healing trend. Because very few control patients achieved wound healing in 4 months, Kaplan-Meier survival analysis was used to compare the relative time to healing for the patients who healed in both groups. According to the Kaplan-Meier estimates, patients in the SNAP™ System group achieved healing in a significantly ($p < 0.0001$) shorter average time (74.25 ± 20.1 days) compared to patients in the Matched Control group (148.73 ± 63.1 days). This represented a 50% absolute reduction in time to healing for patients in the SNAP™ System group. When individual SNAP™ System patients were compared to their 2 matched controls, the average difference in time to healing (54.27 ± 28.1 days) was also significantly ($p < 0.0001$) shorter for the SNAP™ System patients.²³

Fong et al²⁴ (2010) reported the first clinical use of SNAP™ System in a case series of 12 consecutive patients with chronic wounds treated at an academic outpatient dermatology clinic. The study evaluated the safety, feasibility and efficacy of SNAP™ System. The protocol required biweekly clinic visits to document complications and wound healing progress over a 4-week period. All 12 patients experienced at least partial wound healing after SNAP™ System treatment. The 6 patients that met all study requirements (including follow-up visits) had a statistically significant ($p<0.01$) mean wound area reduction of 97.2% at 4 weeks post SNAP™ System initiation. Five of these 6 patients achieved complete wound healing. Nine of the 11 patients who completed the exit survey stated that they would use SNAP™ System if they developed another chronic wound.²⁴

Lerman et al¹⁶ (2010) treated 4 diabetic patients in a WCC to evaluate the safety and efficacy of SNAP™ System as part of a treatment protocol for complex lower extremity wounds. Patients were followed for up to 4 months or wound closure. One patient's wound achieved complete closure after 4 weeks of SNAP™ System, while a second patient's wound closed in 5 weeks, following 4 weeks of SNAP™ System and use of an offloading orthotic. For the remaining 2 patients, SNAP™ System was used to prepare the wound bed by promoting granulation tissue formation followed by placement of APLIGRAF® (Organogenesis, Inc., Canton, MA, USA) in the third patient and a skin graft in the fourth patient. Both of these wounds achieved complete wound closure at 8 weeks after SNAP™ System initiation. The authors commented that SNAP™ System's "off the shelf" availability, simple application process, and "ultraportability" were advantages in the outpatient care setting.¹⁶

In 2015, Bradbury et al²⁵ conducted an observational study of patients with chronic venous leg ulcers (n=15), mixed etiology leg ulcers (n=13), and neuropathic foot ulcers (n=9). While 38 patients were recruited, the Intention-to-Treat analysis was based on the 37 that received the 2 weeks of SNAP™ System required for evaluable patients, who were followed for up to 6 weeks. The primary endpoint was percentage change in wound size between weeks 1 and 8. Four (10.8%) patients discontinued treatment shortly after receiving 2 weeks of SNAP™ System; 33 (89.2%) completed the study. Mean percentage decrease in wound area for the study population as a whole was 42.64% with mean reductions of 64% for venous leg ulcers and 55% for neuropathic foot ulcers. In the 15 patients (41%) who experienced wound infections, SNAP™ System was temporarily suspended (maximum delay of 2 weeks) and restarted after resolution of the infection. The authors noted that infection is generally observed in patients with complex chronic wounds. Skin-related adverse events were also more likely to occur in the 2 leg ulcer groups.²⁵

Awad and Butcher²⁶ (2012) reported the case of a middle-aged male with Type 2 diabetes who developed a new ulceration on the lateral border of his left foot. This was the site of 2 previous ulcerations treated with different battery-powered portable NPWT devices. The third ulceration was extensive and presented over his previous ray amputation. The wound had slough, high exudate levels, heavy bacterial colonization and exposed tendon. SNAP™ System (-125mmHg) was applied with a moistened antimicrobial gauze-interface layer beneath the hydrocolloid dressing and the cartridge was attached to the patient's leg to facilitate movement. After discharge from the hospital the patient returned to "light" work duties, although he had been advised to be non-weight-bearing. During and after discontinuation of SNAP™ System, there was significant wound size reduction, and the wound achieved full closure. The patient preferred SNAP™ System to the 2 prior NPWT devices, because it was lightweight, portable, and silent. As a result the patient's sleep was not disturbed, and his coworkers were not aware that he was undergoing treatment.²⁶

In the case study by Neiderer et al²⁷ (2012), lightweight SNAP™ System was used because the 76-year-old male with rheumatoid arthritis was frail. The patient was originally diagnosed as having a venous leg ulcer (1.8cm x 1.5cm) on his anterior left leg. After 1 month of treatment with moistened gauze, the wound had increased to 4.5cm x 5.0cm. After the diagnosis was changed to pyoderma gangrenosum, the patient was treated with prednisone and topical application of tacrolimus and the wound continued to increase in size (7.2cm x 5.6cm). Treatment was changed to SNAP™ System at -75mmHg with twice weekly dressing changes and APLIGRAF® (Organogenesis, Inc., Canton, MA) applications every 2 weeks for a total of 5 treatments. After 4 weeks, SNAP™ System was increased to -125mmHg based on patient tolerance of the lower pressure and the need for increased exudate control. After 12 weeks, the wound decreased in size to 2.9cm x 2.5cm and was fully epithelialized by 16 weeks after initiation of APLIGRAF® (Organogenesis, Inc., Canton, MA, USA) and SNAP™ System.²⁷

A case study by Awad and Butcher²⁸ (2013) presented use of SNAP™ System to treat a dehiscent surgical breast wound. The 38-year-old female patient had been treated for breast cancer with chemotherapy, breast cancer surgery, and postoperative radiotherapy. A seroma developed and was aspirated prior to radiotherapy; however, during radiotherapy the suture line broke down, resulting in full dehiscence of a deep peri-axillary cavity lined with necrotic tissue. Following debridement, the wound was initially treated with Manuka-honey-based dressings and oral antibiotics were prescribed to address heavy bacterial growth. After 2 weeks, the wound was 6cm long, ≥6cm deep, and lined with soft residual slough. NPWT was recommended. The patient chose SNAP™ System so she could work and take care of her family without others being aware that she was undergoing treatment. SNAP™ System was discontinued after 6 weeks, when the wound had decreased to <1.5cm in depth and was thereafter treated with dressings until closure was achieved.²⁸

As with any case study, the results and outcomes should not be interpreted as a guarantee or warranty of similar results. Individual results may vary depending on the patient's circumstances and condition.

NOTE: Specific indications, contraindications, warnings, precautions and safety information exist for KCI products and therapies. Please consult a physician and product instructions for use prior to application.

Clinical Evidence Supporting SNAP™ THERAPY SYSTEM

Table 1: Key Clinical Evidence Supporting Use of SNAP™ System

Author	Study Type	Patients	Results/Conclusions
<p>DG Armstrong et al²¹</p> <p><i>(Wound Repair and Regeneration; 2012)</i></p>	<ul style="list-style-type: none"> Randomized controlled trial (RCT) SNAP™ System vs V.A.C.® Therapy 	<ul style="list-style-type: none"> 132 patients (pts) with noninfected, nonischemic, nonplantar lower extremity diabetic and venous wounds were enrolled 115/132 pts had follow-up data available for analysis 83 pts finished the study with either healing or 16 weeks of therapy: <ul style="list-style-type: none"> SNAP™ System: 41 pts V.A.C.® Therapy: 42 pts 	<ul style="list-style-type: none"> Primary endpoint was wound size reduction Baseline wound size: SNAP™ System: 5.37 ± 6.14 vs V.A.C.® Therapy: 9.95 ± 11.38 ($p < 0.05$) <ul style="list-style-type: none"> V.A.C.® Therapy wounds were significantly larger than SNAP™ System wounds Study was powered to demonstrate comparative efficacy, noninferiority In terms of wound size reduction, SNAP™ System pts demonstrated noninferiority to V.A.C.® Therapy pts at 4, 8, 12 and 16 weeks ($p = 0.0030, 0.0130, 0.0051$, and 0.0044, respectively) There were no significant differences in complete wound closure at all time points Rates of device-related adverse events and complications (e.g., infection) were also similar between groups Study demonstrated similar wound healing outcomes between SNAP™ System and V.A.C.® Therapy in the study population
<p>WA Marston et al²²</p> <p><i>(Advances in Wound Care, 2015)</i></p>	<ul style="list-style-type: none"> RCT Sub-analysis²¹ SNAP™ System vs V.A.C.® Therapy 	<ul style="list-style-type: none"> 40 pts with venous leg ulcers <ul style="list-style-type: none"> SNAP™ System (n=19) V.A.C.® Therapy (n=21) 	<ul style="list-style-type: none"> Primary endpoint: wound size reduction There were differences in the mean initial wound size: SNAP™ System, $4.85 \pm 4.49\text{cm}^2$ vs V.A.C.® Therapy, $11.60 \pm 12.12\text{cm}^2$ There was no significant difference (without [$p = 0.3547$] or with [$p = 0.4656$] adjustment for baseline wound size) in the proportion of pts that completely healed over time SNAP™ System pts had significantly greater percent wound closure than V.A.C.® Therapy pts at 4, 8, 12, and 16 weeks ($p = 0.0039, 0.0086, 0.0002$, and 0.0005, respectively) 50% wound closure at 30 days: SNAP™ System: 52.6% (10/19) pts vs V.A.C.® Therapy: 23.8% (5/21) pts (odds ratio [OR] 3.56, 95% confidence interval [CI] of [0.923, 13.699]) Complete wound closure at 90 days: SNAP™ System: 57.9% (11/19) pts vs V.A.C.® Therapy: 38.15% (8/21) pts (OR, 2.23, 95% CI [0.63, 7.93])

Table 1: Key Clinical Evidence Supporting Use of SNAP™ System (cont.)

Author	Study Type	Patients	Results/Conclusions
<p>B Lerman et al²³</p> <p>(<i>Plastic and Reconstructive Surgery</i>; 2010)</p>	<ul style="list-style-type: none"> • Prospective comparative study • SNAP™ System vs patient-matched controls 	<ul style="list-style-type: none"> • Prospective Study: 21 wound care center pts with refractory lower extremity ulcers treated with SNAP™ System over a period lasting up to 4 months • Retrospective matched controls (2 unique matches per SNAP™ System patient): 42 pts treated over the preceding 4 years at the same clinic with modern wound care protocols including skin substitutes and skin grafting 	<ul style="list-style-type: none"> • Primary endpoint: Evaluate safety and efficacy of SNAP™ System for treatment of refractory lower extremity ulcers • SNAP™ System group: <ul style="list-style-type: none"> - 100% (21/21) pts demonstrated reduced wound size - 86% (18/21) had a statistically significant healing trend ($p < 0.05$) • Based on Kaplan-Meier estimates, mean time to healing for SNAP™ System group vs matched control group was 74.25 ± 20.1 vs 148.73 ± 63.1 days, respectively; $p < 0.0001$ • This difference represented a 50% absolute reduction in time to healing for the SNAP™ System group • The average difference in time to healing was also significantly ($p < 0.0001$) shorter (54.27 ± 28.1 days), when individual SNAP™ System pts were compared to their 2 matched controls
<p>B Lerman et al¹⁶</p> <p>(<i>Journal of Diabetes Science and Technology</i>; 2010)</p>	<ul style="list-style-type: none"> • Case Series • SNAP™ System 	<ul style="list-style-type: none"> • 4 diabetic pts with refractory lower extremity wounds were treated with SNAP™ System in the outpatient WCC setting 	<ul style="list-style-type: none"> • SNAP™ System duration was 4 weeks in 3 pts and 6 weeks in 1 patient • After use of SNAP™ System for wound bed preparation: <ul style="list-style-type: none"> - 2 wounds achieved complete wound closure - 1 wound was closed with a single application of a bi-layered skin substitute - 1 wound was closed with a skin graft
<p>KD Fong et al²⁹</p> <p>(<i>Wounds</i>; 2010)</p>	<ul style="list-style-type: none"> • Case Series • SNAP™ System 	<ul style="list-style-type: none"> • 12 consecutive adult pts with chronic wounds were followed biweekly for complications and wound healing over a 4-week period • First clinical experience using SNAP™ System on pts 	<ul style="list-style-type: none"> • All 12 pts experienced at least partial wound healing after SNAP™ System treatment • The 6 of 12 pts who met all study requirements had a statistically significant ($p < 0.01$) mean wound area reduction of 97.2% at 4 weeks post SNAP™ System initiation • Five of these 6 pts achieved complete wound healing

Table 1: Key Clinical Evidence Supporting Use of SNAP™ System (cont.)

Author	Study Type	Patients	Results/Conclusions
<p>S Bradbury et al²⁵</p> <p>(<i>Advances in Wound Care</i>; 2015)</p>	<ul style="list-style-type: none"> • Case Series • SNAP™ System 	<ul style="list-style-type: none"> • Of 38 recruited pts, 37 received 2 weeks of SNAP™ System and were considered to be evaluable • The Intention-to-treat analysis was based on data from the 37 evaluable pts who had 1 of 3 types of chronic ulcers: <ul style="list-style-type: none"> - Venous leg ulcers (n=15) - Mixed etiology leg ulcers (n=13) - Neuropathic foot ulcers (n=9) • Four patients discontinued the study shortly after 2 weeks of SNAP™ System • The remaining 33 evaluable pts were followed for up to 6 weeks 	<ul style="list-style-type: none"> • Primary endpoint of percentage change in wound size was met with an overall: <ul style="list-style-type: none"> - Mean percentage decrease of 42.64% in wound area across the study population between weeks 1 and 8 - Mean reduction in wound size of 64% for venous leg ulcers and 55% for neuropathic foot ulcers • 15 (41%) pts developed wound infection • Skin-related adverse events were more likely to occur in the leg ulcer groups
<p>T Awad and M Butcher²⁶</p> <p>(<i>Wounds International</i>; 2012)</p>	<ul style="list-style-type: none"> • Case Series • SNAP™ System 	<ul style="list-style-type: none"> • Middle-aged male with Type 2 diabetes and a history of 2 ulcerations presented with a new infected ulceration on his left foot over his previous ray amputation with exposed tendon 	<ul style="list-style-type: none"> • Antibiotic therapy was commenced • SNAP™ System was applied with a moistened antimicrobial gauze-interface layer beneath the hydrocolloid dressing • NPWT was initiated at -125mmHg; cartridge was attached to pt's leg to facilitate movement • There was significant wound size reduction during and after discontinuation of SNAP™ System, wound achieved full closure • Compared to the prior different 2 battery-powered NPWT devices, pt preferred SNAP™ System because it was light, portable, and easy to use
<p>K Neiderer et al²⁷</p> <p>(<i>Ostomy Wound Management</i>; 2012)</p>	<ul style="list-style-type: none"> • Case Series • SNAP™ System 	<ul style="list-style-type: none"> • A 76-year-old male with a history of rheumatoid arthritis presented with a venous leg ulcer (1.8cm x 1.5cm) on his anterior left leg; the wound was re-diagnosed as pyoderma gangrenosum (PG) after failed treatment 	<ul style="list-style-type: none"> • Pt began treatment with APLIGRAF® (Organogenesis, Inc., Canton, MA) applied every 2 weeks for a total of 5 applications and SNAP™ System with twice weekly dressing changes • Because of pt frailty, SNAP™ System was chosen because of its lightweight; initial negative pressure of -75mmHg was increased to -125mmHg after 4 weeks to better control exudate • After 12 weeks, the wound decreased to 2.9cm x 2.5cm and fully epithelialized at 16 weeks after initiation of APLIGRAF® (Organogenesis, Inc., Canton, MA) and SNAP™ System

Table 1: Key Clinical Evidence Supporting Use of SNAP™ System (cont.)

Author	Study Type	Patients	Results/Conclusions
T Awad and M Butcher ²⁸ (<i>Journal of Wound Care</i> ; 2013)	<ul style="list-style-type: none">• Case Series• SNAP™ System	<ul style="list-style-type: none">• A 38-year-old woman was treated for breast cancer with chemotherapy, breast cancer surgery and postoperative radiotherapy• Development of a seroma during radiotherapy eventually resulted in full suture line dehiscence, revealing a deep cavity lined with necrotic tissue• Post 2 weeks of treatment with debridement, the peri-axillary wound was 6cm long, ≥6cm deep and lined with soft residual slough	<ul style="list-style-type: none">• When NPWT was recommended, the pt chose SNAP™ System because she could work and take care of her family without others being aware that she was undergoing treatment• After 6 weeks of treatment, the wound was <1.5cm deep, and SNAP™ System was replaced with dressings until wound closure

Technology for SNAP™ System

In the mechanically powered SNAP™ System, a set of specialized constant force springs creates the forced air expansion that maintains a predetermined negative pressure³⁰ even as the built-in canister fills with exudate. BIOLOCK™ Technology turns the exudate into a gel for improved containment in the cartridge. The use of mechanical (rather than electrical) power provides silent therapy that can facilitate discreet treatment in a work or social environment and cause less sleep disruption.

Similar to electrically-powered NPWT systems, mechanically-powered SNAP™ System draws wound edges together and removes infectious material and exudate from the wound (**Figure 2**).

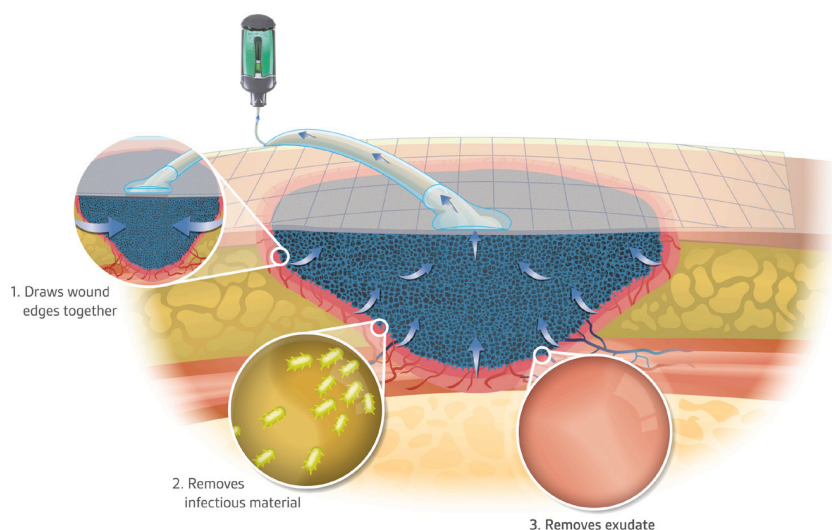


Figure 2. SNAP™ System helps to promote wound healing by drawing wound edges together and removing small amounts of infectious material and exudate.

Indications for Use

The SNAP™ System is indicated for patients who would benefit from wound management via the application of negative pressure, particularly as the device may promote wound healing through the removal of excess exudate, infectious material and tissue debris. The SNAP™ System is indicated for removal of small amounts of exudate from chronic, acute, traumatic, subacute and dehisced wounds, partial-thickness burns, ulcers (such as diabetic, venous, or pressure), surgically closed incisions, flaps and grafts.

Contraindications

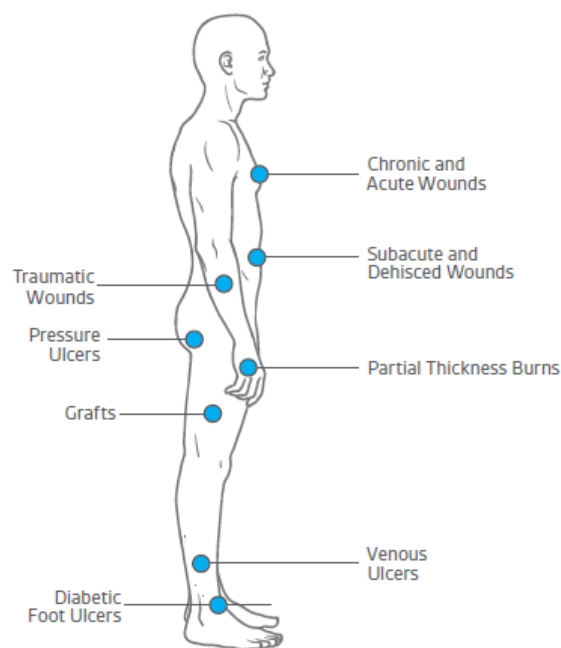
The SNAP™ System should not be applied over:

- Inadequately drained wounds
- Necrotic tissue, such as eschar or adherent slough
- Exposed blood vessels, anastomotic sites, organs, tendons or nerves
- Wounds containing malignancy
- Fistulas
- Untreated osteomyelitis
- Actively bleeding wounds

Warnings, Precautions, and Limitations

The SNAP™ Therapy Cartridge and fitting are not indicated for use in a hyperbaric oxygen therapy environment.

It is important to read and follow all instructions and safety information prior to use for any NPWT device.



SNAP™ THERAPY SYSTEM Components*



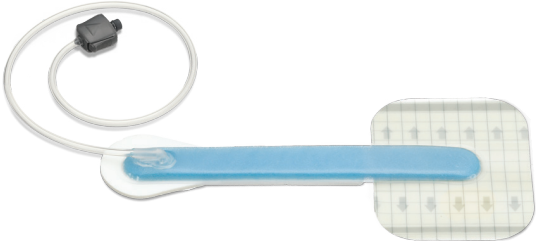
The SNAP™ System cartridge, strap, interface layer and dressings are described in Table 2.

Table 2: SNAP™ System components and accessories

Name/Description	Picture
<p>SNAP™ Therapy Cartridge</p> <p>Removal of the Activation/Reset Key from the SNAP™ Therapy Cartridge initiates delivery of negative pressure (-75mmHg, -100mmHg, or -125mmHg).</p> <p>These cartridges hold up to 60ml of exudate. BIOLOCK™ Technology turns the exudate into a gel to optimize containment.</p>	
<p>SNAP PLUS™ 125mmHg Therapy Cartridge</p> <p>A larger SNAP™ Therapy Cartridge is available that holds up to 150ml of exudate and delivers -125mmHg of negative pressure.</p> <p>The 150ml cartridge uses BIOLOCK™ Technology, which turns the exudate into a gel to optimize containment.</p>	
<p>SNAP™ Therapy Strap</p> <p>The SNAP™ Therapy Strap enables the 60ml cartridge to be worn conveniently under clothing.</p> <p>The strap comes in 3 sizes: Small (46cm), Medium (53cm), and Large (61cm).</p>	
<p>SNAP PLUS™ Therapy Strap</p> <p>The SNAP PLUS™ Therapy Strap enables the 150ml cartridge to be placed into a carrying case and attached to the patient.</p> <p>The strap comes in 3 sizes: Small (46cm), Medium (53cm), and Large (61cm).</p>	
<p>Interface Layers</p> <p>The blue foam interface layers come in small (8cm x 8cm), medium (13cm x 13cm), and large (18cm x 18cm, not shown) sizes and facilitate even levels of negative pressure in the wound bed.</p>	

*Subject to market availability.

Table 2: SNAP™ System components (cont.)

Name/Description	Picture
<p>SNAP™ SecurRing™ Hydrocolloid</p> <p>The SNAP™ SecurRing™ Hydrocolloid increases the adhesion of the SNAP™ Dressing on dry and uneven skin.</p>	
<p>SNAP™ Hydrocolloid Dressing</p> <p>The hydrocolloid dressing comes in various sizes (20cm x 20cm, 15cm x 15cm, or 10cm x 10cm) with fully-integrated microport that allows a tight bending radius for wounds in difficult locations, and cut-to-length tubing with integrated one-way flow valve.</p> <p>The dressing can be customized and shaped to fit around challenging body contours to facilitate sealing.</p>	 <p>Interface layer not shown.</p>
<p>SNAP™ Bridge Dressing</p> <p>The bridge dressing includes a completely flat dressing (14cm x 11cm, or 14cm x 11cm with SNAP™ SecurRing™ Hydrocolloid) to help minimize pressure damage and has a built-in bridge and port for one-step application. There is soft pad cushioning under the foam bridge to improve patient comfort.</p>	 <p>Interface layer not shown.</p>

Science Supporting SNAP™ System

Scientific studies have been conducted to evaluate the ability of SNAP™ System to deliver NPWT. Because maintenance of a prescribed level of negative pressure is critical for NPWT, a scientific bench study compared the ability of both SNAP™ System and V.A.C.® Therapy to maintain target negative pressure (-125mmHg) with and without exudate inflow in a simulated wound model. Results indicated that with and without fluid in the model, SNAP™ System delivered negative pressure (at -125mmHg set point) similar to that delivered by V.A.C.® Therapy over a 24-hour period.³⁰

An animal study was used to evaluate SNAP™ System's ability to produce granulation tissue. Rats with surgically created 2.5cm x 3cm wounds were treated with either SNAP™ System at -125mmHg or the SNAP™ Dressing without negative pressure. Animals treated with SNAP™ System at -125mmHg had a significantly greater wound size reduction at 7 days compared to those treated with the SNAP™ Dressing and no negative pressure: 51% vs. 12%, respectively, $p < 0.05$.³⁰ This rodent study was modeled on a previous study in which animals treated with a V.A.C.® Therapy Dressing and negative pressure at -125mmHg achieved a 40% decrease in wound size.³¹ According to the authors, the similarity of results in these animal studies "suggests that the SNAP™ System may have efficacy equal to that of vacuum assisted closure for some wounds."³⁰

Case Studies

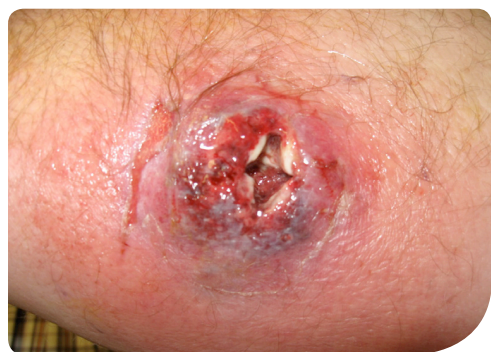As with any case study, the results and outcomes should not be interpreted as a guarantee or warranty of similar results. Individual results may vary, depending on the patient's circumstances and condition.

Case Study 1: *Venomous Insect Bite*

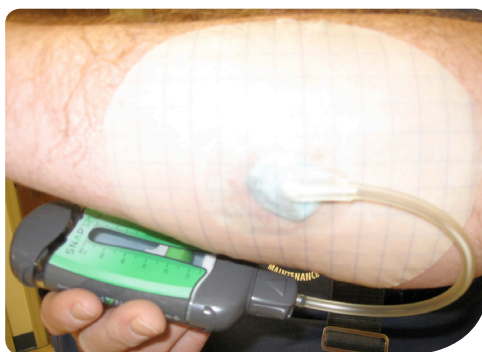Patient was a 58-year-old male who presented with an apparent insect bite on the left forearm. He initially noted a red pimple forming on the skin which rapidly enlarged over 2 weeks with increasing pain and swelling of the arm. He was immediately referred for hyperbaric oxygen therapy (HBOT) which was started the next day.

Irrigation and drainage was completed 48 hours after his initial presentation which revealed a large, crater-like defect extending to the muscle with minimal exudate or purulence (**Figure 3A**). After 2 days of wound packing with silver alginate and continued HBOT, the peri-wound inflammation had subsided and the wound bed colour had improved. Negative pressure wound therapy using the SNAP™ 125mmHg Therapy Cartridge with the SNAP™ Advanced Dressing Kit (KCI, an ACCELITY Company, San Antonio, TX, USA) was initiated (**Figure 3B**), and after only two dressing applications the wound volume was completely reduced (**Figure 3C**). The patient was able to continue working while utilizing negative pressure therapy and did not require disability. He went on to complete closure, only requiring 17 HBOT treatments and 6 weeks of care (**Figure 3D**).

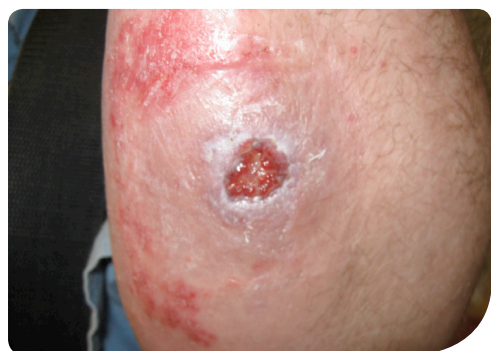Figure 3. Venomous Insect Bite



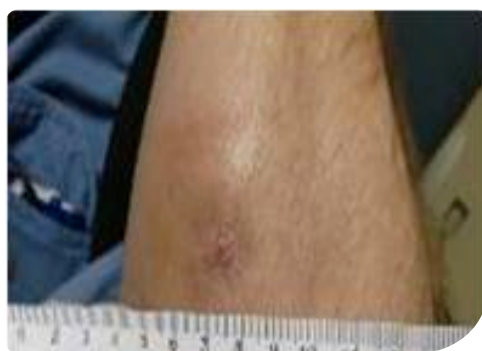A. Wound appearance after irrigation and drainage; 48 hours after presentation



B. Application of SNAP™ System, 2 days post irrigation and drainage



C. Reduced wound volume after two dressing applications



D. Wound closure after 6 weeks

Patient data and photos courtesy of Christopher L. Barrett, DPM, CWS, FACCWS; Crozer Chester Medical Center, Chester, PA, USA

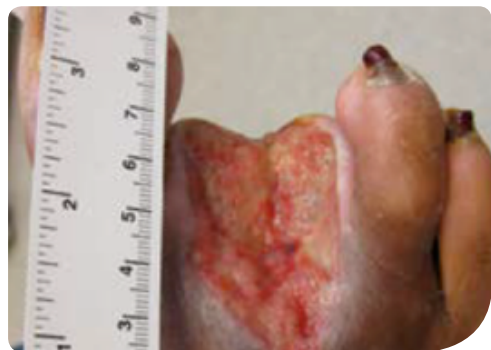Case Study 2: Diabetic Amputation Wound

A 62-year-old female was hospitalized for infected gangrenous toes resulting from her neuropathic diabetes and peripheral vascular disease. The patient was taken to the operating room and found to have osteomyelitis of the 2nd and 3rd ray and underwent partial amputations. The resulting wound was extensive, involving all the soft tissue overlying the metatarsophalangeal joints and extending to the mid shaft of the 2nd and 3rd metatarsals. When the patient presented to the wound care center, the wound bed had become necrotic with exposed bone and calcified vessels. She underwent debridement and dressing changes with Dakin's Solution® (quarter strength) (Century Pharmaceuticals, Inc., Indianapolis, IN). After approximately 1 month of traditional wound therapy, the infection appeared to have cleared, but there remained a large wound with exposed bone and minimal granulation tissue.

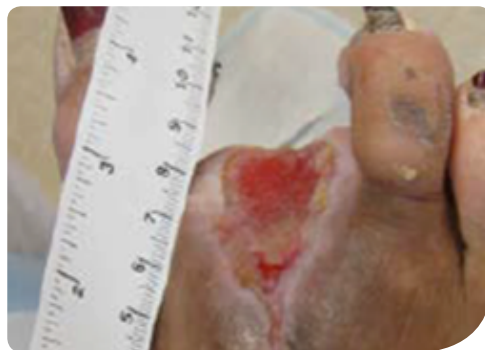Prior to treatment with the SNAP™ System, the wound measured 65mm x 36mm with a depth of 6mm without undermining (**Figure 4A**). The patient had a complex medical history, most notable for insulin-dependent diabetes, peripheral vascular disease, hypertension, and hyperlipidemia.

The patient achieved full granulation of the wound bed and complete soft-tissue coverage of exposed bone as a result of 4 and 6 weeks of treatment with the SNAP™ System with bi-weekly dressing changes (**Figures 4B and 4C**). The wound was then closed with an advanced cellular matrix. Wound closure was achieved at 10 weeks post-initiation of the SNAP™ System (**Figure 4D**).

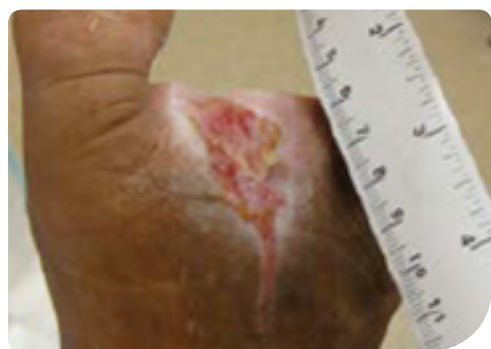Figure 4. Diabetic Amputation Wound



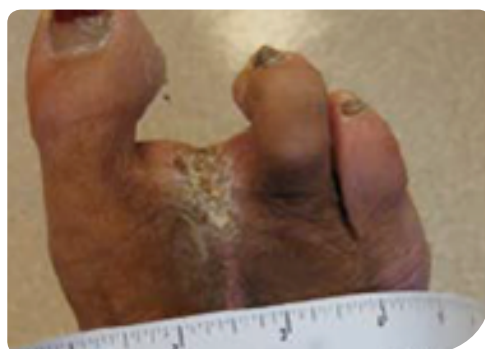A. Wound at start of SNAP™ System



B. Development of granulation tissue after 4 weeks of SNAP™ System



C. Further granulation tissue development after 6 weeks of SNAP™ System



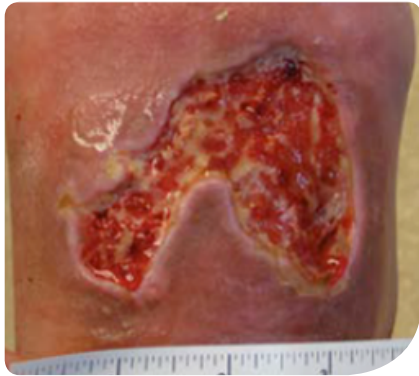D. Wound fully healed 11 weeks post presentation

Case Study 3: Traumatic Wound

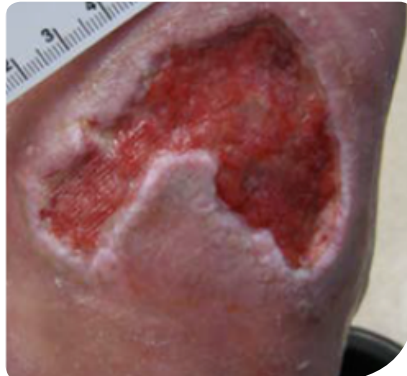A 68-year-old male presented with a traumatic wound to the dorsal foot measuring 70mm x 54mm with a depth of 4mm (**Figure 5A**). Patient medical history included diabetes mellitus, tobacco use, peripheral vascular disease, coronary artery disease, chronic obstructive pulmonary disease, hypertension, and hyperlipidemia.

The patient was treated with the SNAP™ System for 3 weeks until full granulation of the wound was achieved. Then, the therapy was used in conjunction with a cellular tissue product for an additional 5 weeks. Granulation tissue development was observed in the wound after 2 weeks of SNAP™ System use (**Figure 5B**). Wound closure was achieved after 8 weeks of SNAP™ System and cellular tissue product use (**Figure 5C**).

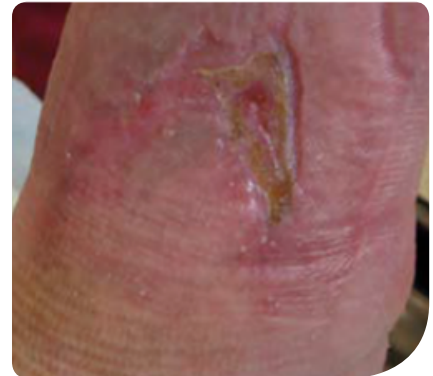Figure 5. Traumatic Wound



A. Wound at start of SNAP™ System use



B. Granulation tissue development observed after 2 weeks of SNAP™ System use



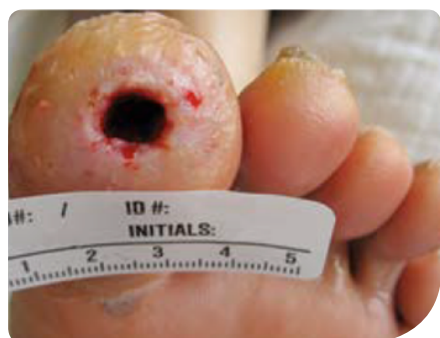C. Wound closure achieved after 8 weeks of SNAP™ System use

Case Study 4: Diabetic Hallux Wound

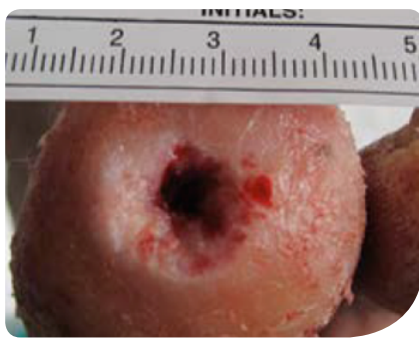
The patient was a 52-year-old male with an ulcer on his left hallux present for 9 months. He reported the ulcer first appeared as a blister from a pair of tight fitting shoes. Previous medical history included diabetes mellitus. Previous treatments included daily silver sulfadiazine dressing changes and weekly debridement. The wound extended to bone and required aggressive bedside debridement. Following debridement, the wound measured 9mm x 8mm with a depth of 20mm without undermining (**Figure 6A**).

The patient was started on the SNAP™ System to help granulate the wound. At week 5, SNAP™ System use was discontinued due to the small size of the wound, and a cellular tissue product was applied (**Figure 6B**). The patient was continued in a postoperative shoe and crest pad. One week after the cellular tissue product application, 8 weeks post presentation, the wound was completely epithelialized (**Figure 6C**). The patient was followed for an additional 2 months at increasing intervals and the wound remained healed.

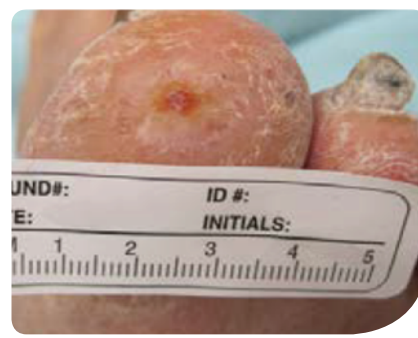Figure 6. Diabetic Hallux Wound



A. Wound at start of SNAP™ System use



B. Wound after 5 weeks of SNAP™ System use



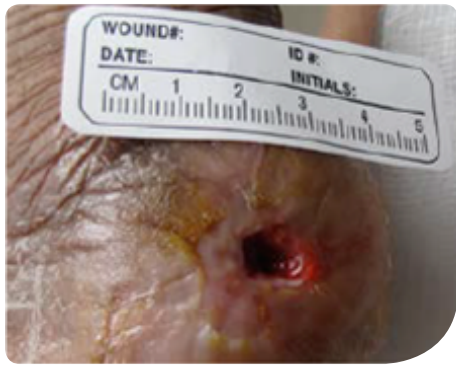C. Wound fully epithelialized 8 weeks post presentation

Case Study 5: Heel Pressure Ulcer

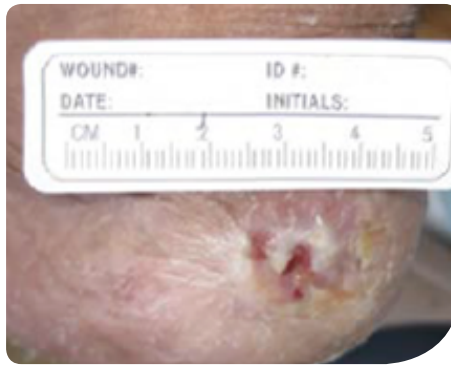A 91-year-old female presented with a pressure ulcer on the left posterior heel measuring 9mm x 7mm with a depth of 5mm (**Figure 7A**). The wound had been present for 9 months. Previous treatments included a cellular tissue product, a silver dressing, and a heel lift boot. Patient medical history included hypertension and peripheral artery disease.

The wound was treated with the SNAP™ System for 9 days for a total of 3 dressing applications with an average application time of 6.3 minutes (**Figure 7B**). Complete epithelialization and wound closure was achieved 1 week after SNAP™ System use was discontinued.

Figure 7. Heel Pressure Ulcer



A. Wound at start of SNAP™ System use



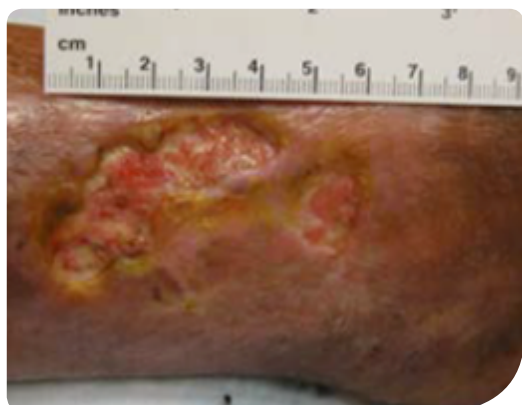B. Wound after 9 days of SNAP™ System use

Case Study 6: Refractory Venous Ulcer

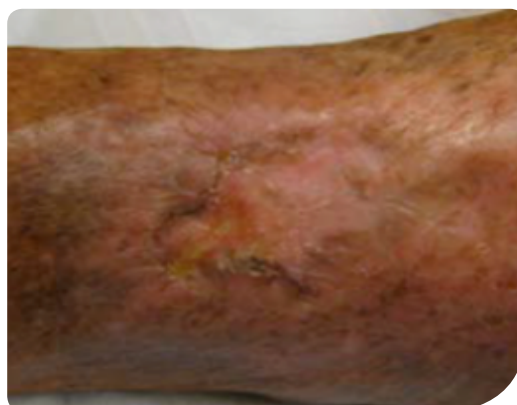An 88-year-old female presented with two diabetic/venous stasis ulcer present for over one year without wound closure. One wound measured 47mm x 22mm with a depth of 3mm (**Figure 8A**) and the second wound measured 9mm x 14mm with a depth of 2mm. Previous medical history included diabetes mellitus, peripheral artery disease, rheumatoid arthritis, venous insufficiency, hypertension, asthma, and prednisone use.

Previous treatment occurred for over one year in a wound care center with compression and multiple modern dressings/therapies including platelet-derived growth factor therapy. However, wound closure was never achieved. The SNAP™ System was initiated and continued for 11 weeks until wound closure (**Figure 8B**).

Figure 8: Refractory Venous Ulcer



A. Wound at start of SNAP™ System use



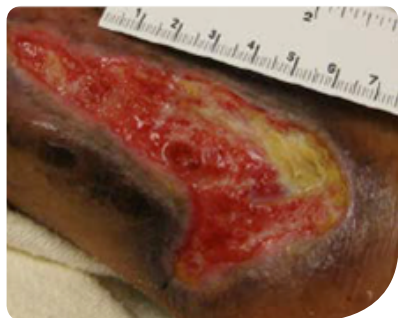B. Wounds fully healed 12 weeks post-initiation of SNAP™ System use

Case Study 7: Venous Ulcer

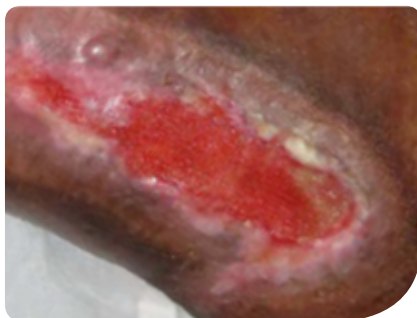The patient (a 77-year-old female) presented with a venous ulcer present for over 8 months, continuing to enlarge in size despite wound care with modern dressings and treatment with a cellular tissue product. The wound measured 84mm x 45mm with a depth of 4mm without undermining (**Figure 9A**). Patient medical history included diabetes mellitus, severe peripheral artery disease, tobacco use, chronic obstructive pulmonary disease, hypertension, hyperlipidemia, bone cancer, and severe malnutrition (<40kgs).

The patient was treated with the SNAP™ System for 11 weeks until full granulation of the wound bed was achieved (**Figure 9B**). The SNAP™ System was then used in conjunction with a cellular tissue product for an additional 3 weeks. Wound closure was achieved 4 months post-initiation of SNAP™ System use (**Figure 9C**).

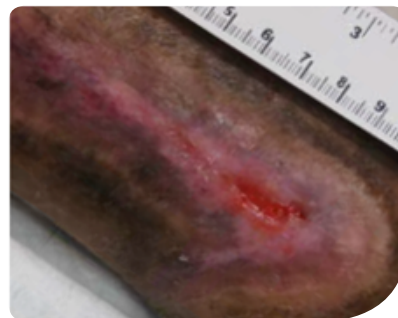Figure 9. Venous Ulcer



A. Wound at start of SNAP™ System use



B. Wound after 3 months of SNAP™ System use

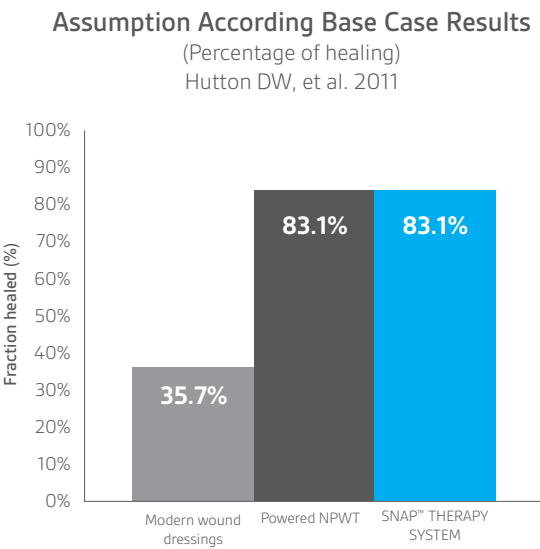


C. Wound fully healed 4 months post-initiation of SNAP™ System use

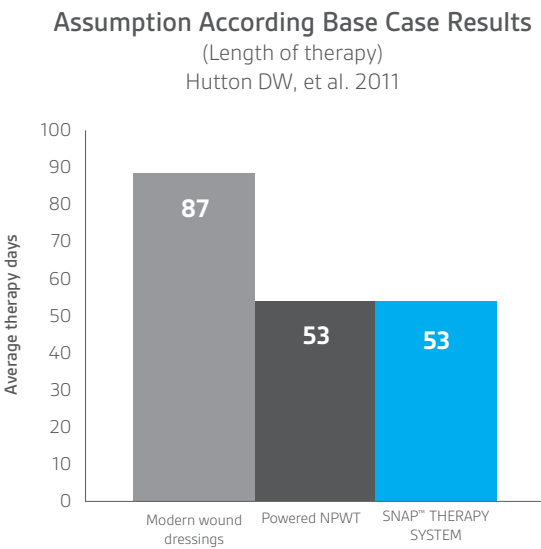
Health Economics

In 2011, Hutton and Sheehan³² analyzed costs and effectiveness of 3 therapies for treatment of diabetic lower extremity wounds: modern wound dressings, powered NPWT, and non-powered SNAP™ System. An economic model using peer-reviewed data was used to simulate outcomes for the different treatments. The proportion of patients expected to heal over a period of 16 weeks was used to measure costs and effectiveness, because the 16-week time period was standard for NPWT trials. Healing progress was modeled as “exponential decay of individuals remaining in therapy each week.”³² The model incorporated healing and complication rates in the literature for diabetic foot wounds and recent SNAP™ System studies. The model also assumed equal efficacy between SNAP™ System and powered NPWT based on clinical study results.³²

Based on the model, Hutton and Sheehan reported that, compared to modern dressings, SNAP™ System saved over \$9,000 USD per wound treated by avoiding longer treatment times and costs for complications and healing more wounds than the modern dressings. Healing time was similar for NPWT and SNAP™ System; however, Medicare and private Payor costs were \$2,300 and \$2,800 less, respectively, for SNAP™ System patients. The authors concluded that, in addition to cost savings, SNAP™ System also allowed patients greater mobility.³²

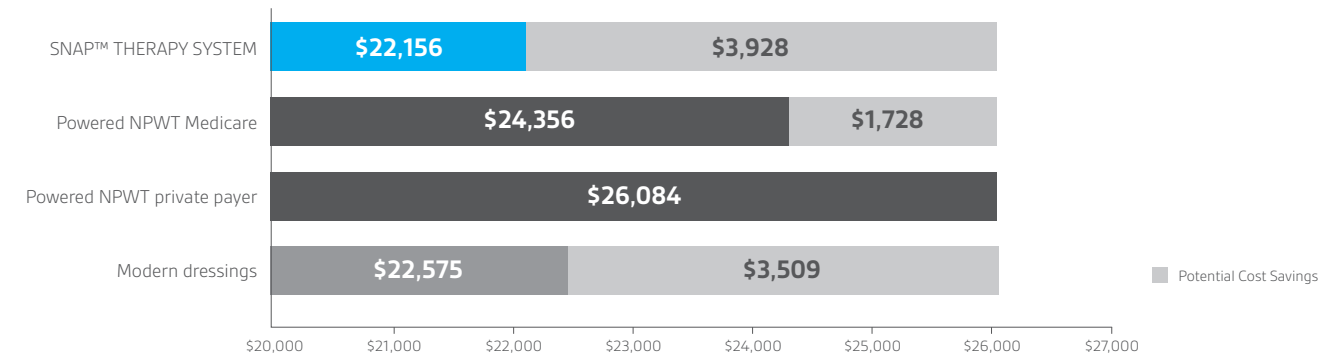


All numbers are averages per patient treated. Effectiveness results are during 16 weeks of therapy.



All numbers are averages per patient treated. Effectiveness results are during 16 weeks of therapy.

Economic Value
Hutton DW, et al. 2011



An economic model with peer-reviewed data was used to simulate outcomes for treatment with different therapies. The model uses the best available data on each of the therapies and uses a modelling approach to predict the outcomes. All numbers are averages per patient treated. Numbers are given in USD (\$).

References

- (1) Centers for Disease Control and Prevention. National Diabetes Statistics Report, 2014: Estimates of Diabetes and Its Burden in the United States. www.cdc.gov, 2014; Available from: *Centers for Disease Control and Prevention*. Accessed September 30, 2015.
- (2) Fife CE, Wall V, Carter MJ, Walker D, Thomson B. Examining the relationship between physician and facility level-of-service coding in outpatient wound centers: results of a multicenter study. *Ostomy Wound Management*. 2012;58:20-22, 24, 26-8.
- (3) Sen CK, Gordillo GM, Roy S Et al. Human skin wounds: a major and snow-balling threat to public health and the economy. *Wound Repair Regen*. 2009;17:763-771.
- (4) Kim PJ, Evans KK, Steinberg JS, Pollard ME, Attinger CE. Critical elements to building an effective wound care center. *J Vascular Surgeons*. 2013;57:1703-1709.
- (5) Fishman TD. How To Manage Venous Stasis Ulcers. *Podiatry Today*. 2007;20:66-72.
- (6) Khanolkar MP, Bain SC, Stephens JW. The Diabetic Foot. *QJM: An International Journal of Medicine*. 2008;101:685-695.
- (7) Wicke C, Bachinger A, Coerper S, Beckert S, Witte MB, Konigsrainer A. Aging influences wound healing in patients with chronic lower extremity wounds treated in a specialized Wound Care Center. *Wound Repair Regen*. 2009;17:25-33.
- (8) Ayello EA, Lyder CH. A New Era of Pressure Ulcer Accountability in Acute Care. *Advanced Skin Wound Care*. 2008;21:134-140.
- (9) Fife C, Walker D, Thomson B, Carter M. Limitations of Daily Living Activities in Patients with Venous Stasis Ulcers Undergoing Compression Bandaging: Problems with the Concept of Self-Bandaging Wounds. 2007;19:255-257.
- (10) Schultz GS, Sibbald RG, Falanga V et al. Wound bed preparation: a systematic approach to wound management. *Wound Repair Regen*. 2003;11:S1-S28.
- (11) Sibbald RG, Orsted H, Schultz GS, Coutts P, Keast D. Preparing the wound bed 2003: focus on infection and inflammation. *Ostomy Wound Management*. 2003;49:24-51.
- (12) Sibbald RG, Elliott JA, Ayello EA, Somayaji R. Optimizing the Moisture Management Tightrope with Wound Bed Preparation 2015. *Advances in Skin and Wound Care*. 2015;28:466-476.
- (13) Morykwas MJ, Simpson J, Pungner K, Argenta A, Kremers L, Argenta J. Vacuum-assisted closure: state of basic research and physiologic foundation. *Plastic Reconstructive Surgery*. 2006;117:121S-126S.
- (14) Orgill DP, Bayer LR. Negative pressure wound therapy: past, present and future. *International Wound Journal*. 2013;10:15-19.
- (15) Willy C, Voelker HU, Englehardt M. Literature On the Subject of Vacuum Therapy: Review and Update 2006. *European Journal of Trauma and Emergency Surgery*. 2007;33:33-39.
- (16) Lerman B, Oldenbrook L, Ryu J, Fong KD, Schubart PJ. The SNaP Wound Care System: A Case Series Using a Novel Ultraportable Negative Pressure Wound Therapy Device for the Treatment of Diabetic Lower Extremity Wounds. *Journal of Diabetes Science and Technology*. 2010;4:825-830.
- (17) Robson MC, Hill DP, Woodske ME, Steed DL. Wound Healing Trajectories as Predictors of Effectiveness of Therapeutic Agents. *Archives of Surgery*. 2000;135:773-777.
- (18) Steed DL, Hill DP, Woodske ME, Payne WG, Robson MC. Wound healing trajectories as outcome measures of venous stasis ulcer treatment. *International Wound Journal*. 2006;3:40-47.
- (19) Sheehan P, Jones P, Caselli A, Giurini JM, Veves A. Percent change in wound area of diabetic foot ulcers over a 4-week period is a robust Predictor of Complete Healing in a 12-Week Prospective Trial. *Diabetes Care*. 2003;26:1879-1882.
- (20) Warriner RA, Snyder RJ, Cardinal MH. Differentiating diabetic foot ulcers that are unlikely to heal by 12 weeks following achieving 50% percent area reduction at 4 weeks. *International Wound Journal*. 2011;8:632-637.
- (21) Armstrong DG, Marston WA, Reyzelman AM, Kirsner RS. Comparative effectiveness of mechanically and electrically powered negative pressure wound therapy devices: a multicenter randomized controlled trial. *Wound Repair and Regen*. 2012;20(3):332-341.
- (22) Marston WA, Armstrong DG, Reyzelman AM, Kirsner RS. A Multicenter Randomized Controlled Trial Comparing Treatment of Venous Leg Ulcers Using Mechanically Versus Electrically Powered Negative Pressure Wound Therapy. *Adv Wound Care*. 2015;4(2):75-82.
- (23) Lerman B, Oldenbrook L, Eichstadt SL, Ryu J, Fong KD, Schubart PJ. Evaluation of chronic wound treatment with the SNAP™ wound care system versus modern dressing protocols. *Plastic and Reconstructive Surgery*. 2010;126(4):1253-61.
- (24) Fong KD, Marston WA. SNaP® Wound Care System: Ultraportable Mechanically Powered Negative Pressure Wound Therapy. *Advanced Wound Care*. 2012;1:41-43.
- (25) Bradbury S, Walkley N, Ivins N, Harding K. Clinical Evaluation of a Novel Topical Negative Pressure Device in Promoting Healing in Chronic Wounds. *Advanced Wound Care*. 2015;4:346-357.
- (26) Awad T, Butcher M. Managing diabetic foot ulceration with a new, highly portable NPWT device. *Wounds International*. 2012;3:40-44.
- (27) Neiderer K, Martin B, Hoffman S, Jolley D, Dancho J. A Mechanically Powered Negative Pressure Device Used in Conjunction with a Bioengineered Cell-Based Product for the Treatment of Pyoderma Gangrenosum: A Case Report. *Ostomy Wound Management*. 2012;58:44-48.
- (28) Awad T, Butcher M. Handling the sequelae of breast cancer treatment: use of NPWT to enhance patient independence. *Journal of Wound Care*. 2013;22:162, 164-166.
- (29) Fong KD, Hu D, Eichstadt SL Et al. Initial clinical experience using a novel ultraportable negative pressure wound therapy device. *Wounds*. 2010;22:230-236.
- (30) Fong KD, Hu D, Eichstadt S Et al. The SNaP system: biomechanical and animal model testing of a novel ultraportable negative-pressure wound therapy system. *Plastic Reconstructive Surgery*. 2010;125:1362-1371.
- (31) Isago T, Nozaki M, Kikuchi Y, Honda T, Nakazawa H. Effects of Different Negative Pressures on Reduction of Wounds in Negative Pressure Dressings. *Journal of Dermatology*. 2003;30:596-601.
- (32) Hutton DW, Sheehan P. Comparative effectiveness of the SNaP™ Wound Care System. *International Wound Journal*. 2011;8:196-205.

SNAP™

THERAPY SYSTEM

NOTE: Specific indications, contraindications, warnings, precautions and safety information exist for KCI products and therapies. Please consult a clinician and product instructions for use prior to application.

Copyright 2017/2018 KCI Licensing, Inc. All rights reserved. Unless otherwise designated, all trademarks are proprietary to KCI Licensing, Inc., its affiliates and/or licensors. PRA000971-RO-OUS, EN (01/18)

